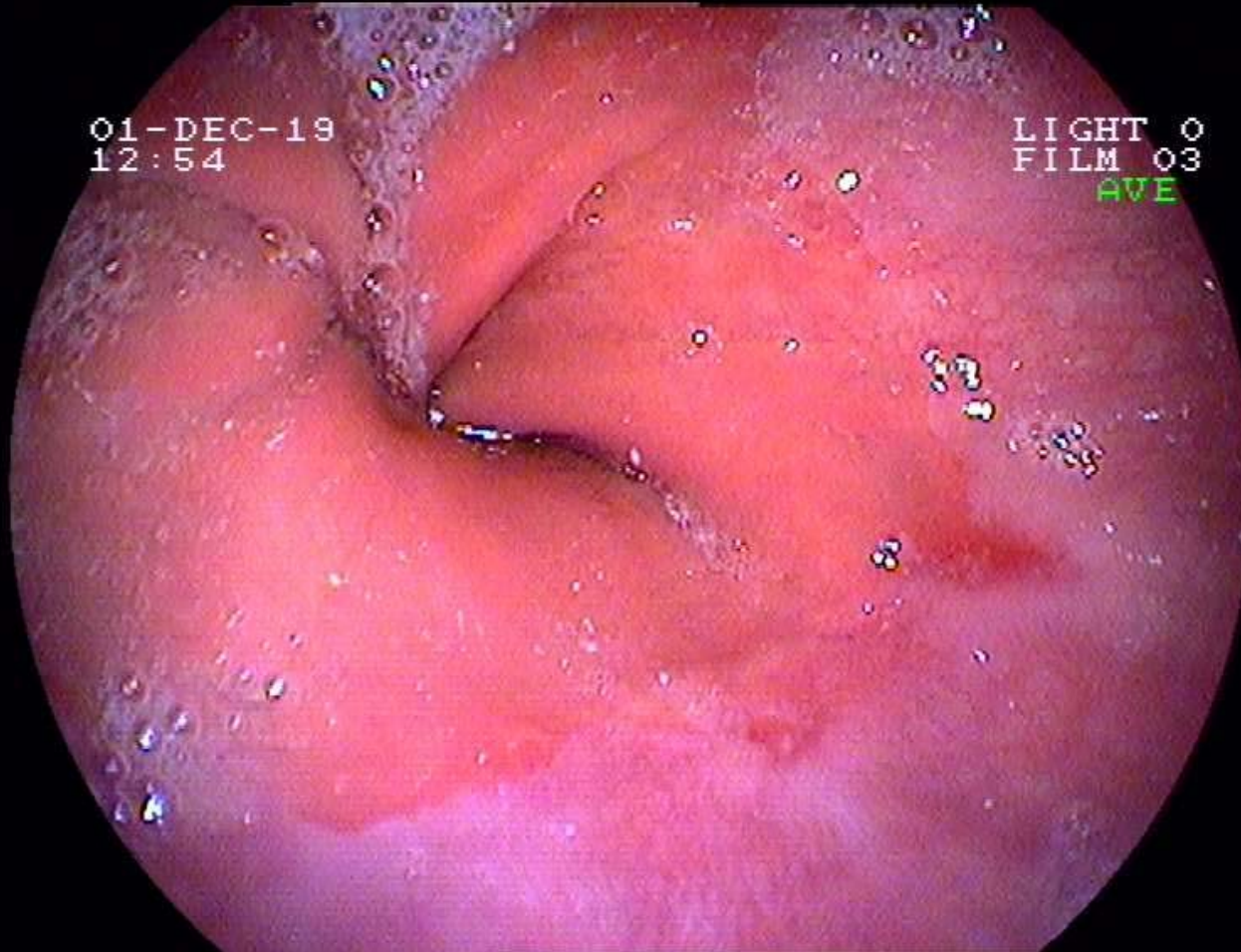


Reflux-Oesophagitis

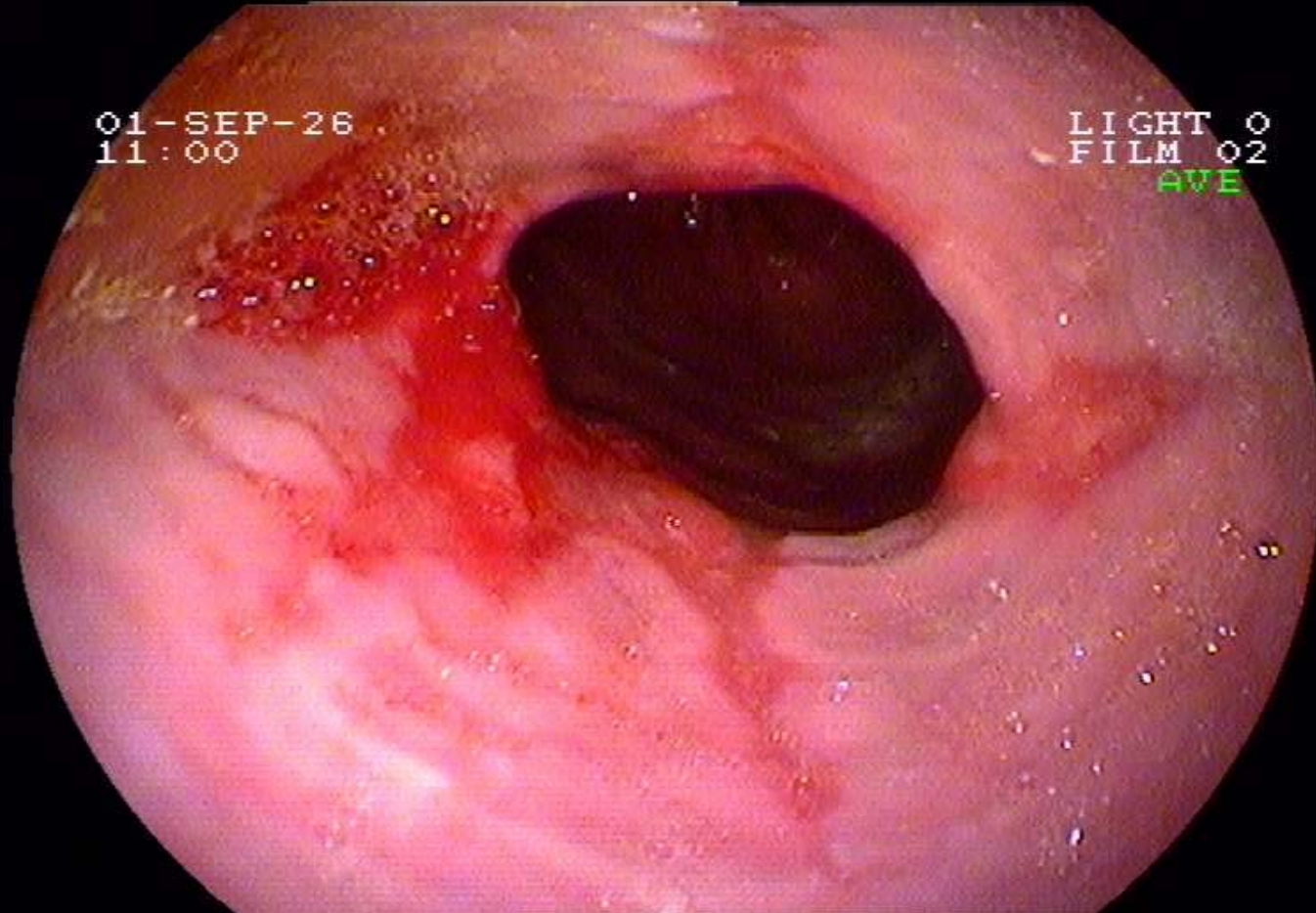
Savary-Miller - Klassifikation



Grad I: Nicht-konfluierende Erosion(en) auf einer oder mehreren Falten

Reflux-Oesophagitis

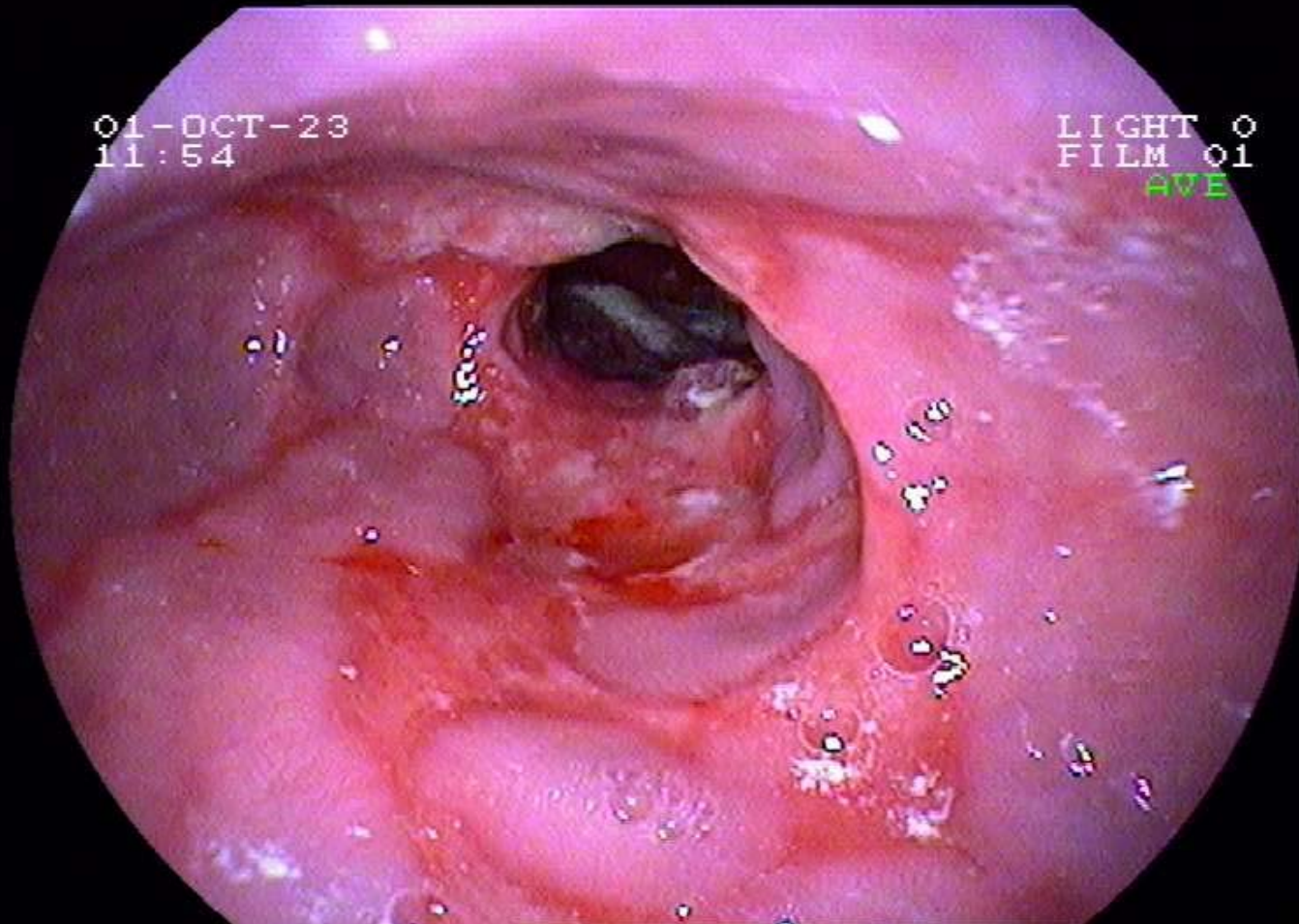
Savary-Miller - Klassifikation



Grad II: Konfluierende Erosionen auf mehreren Falten

Reflux-Oesophagitis

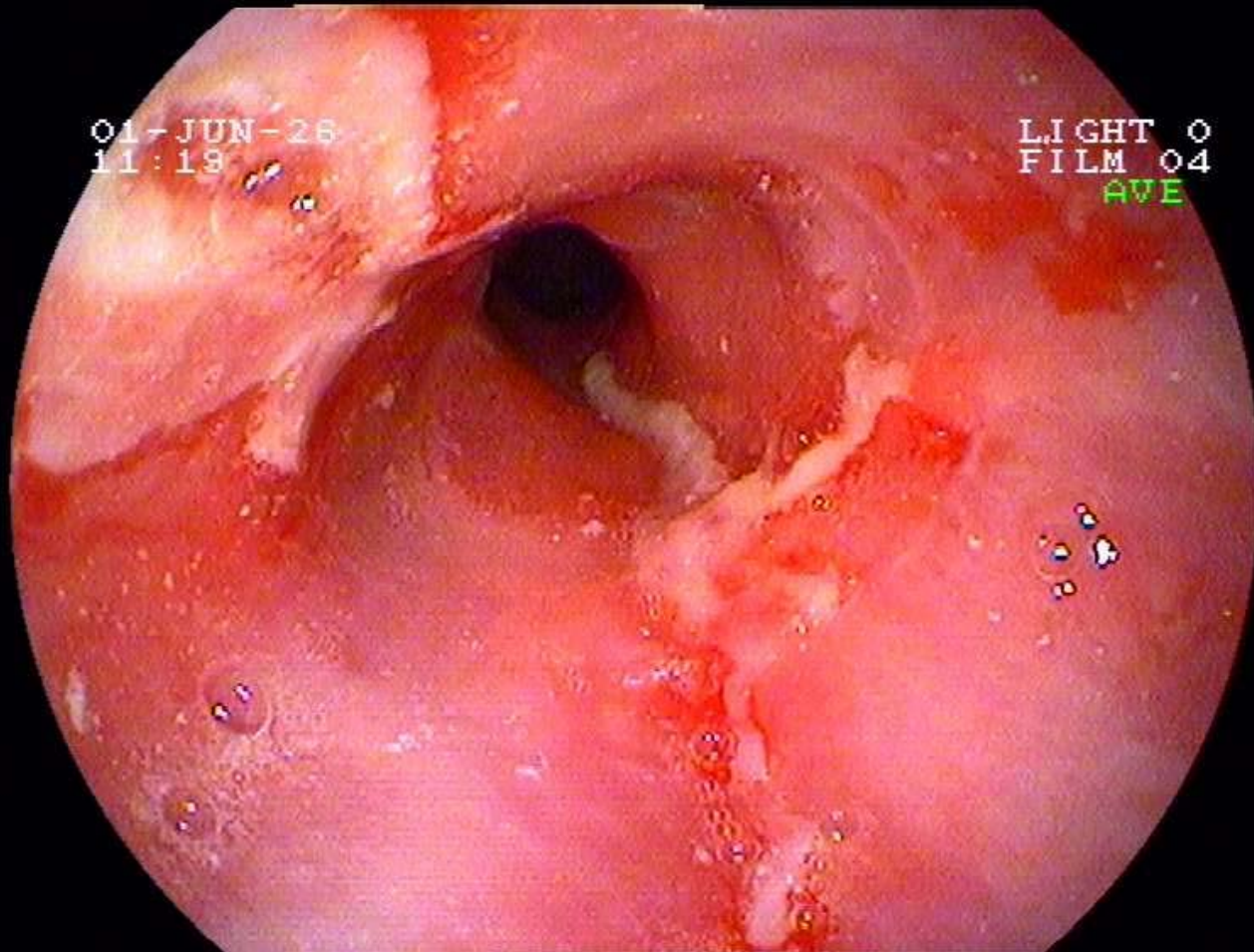
Savary-Miller - Klassifikation



Grad III: Zirkulär konfluierende Erosionen

Reflux-Oesophagitis

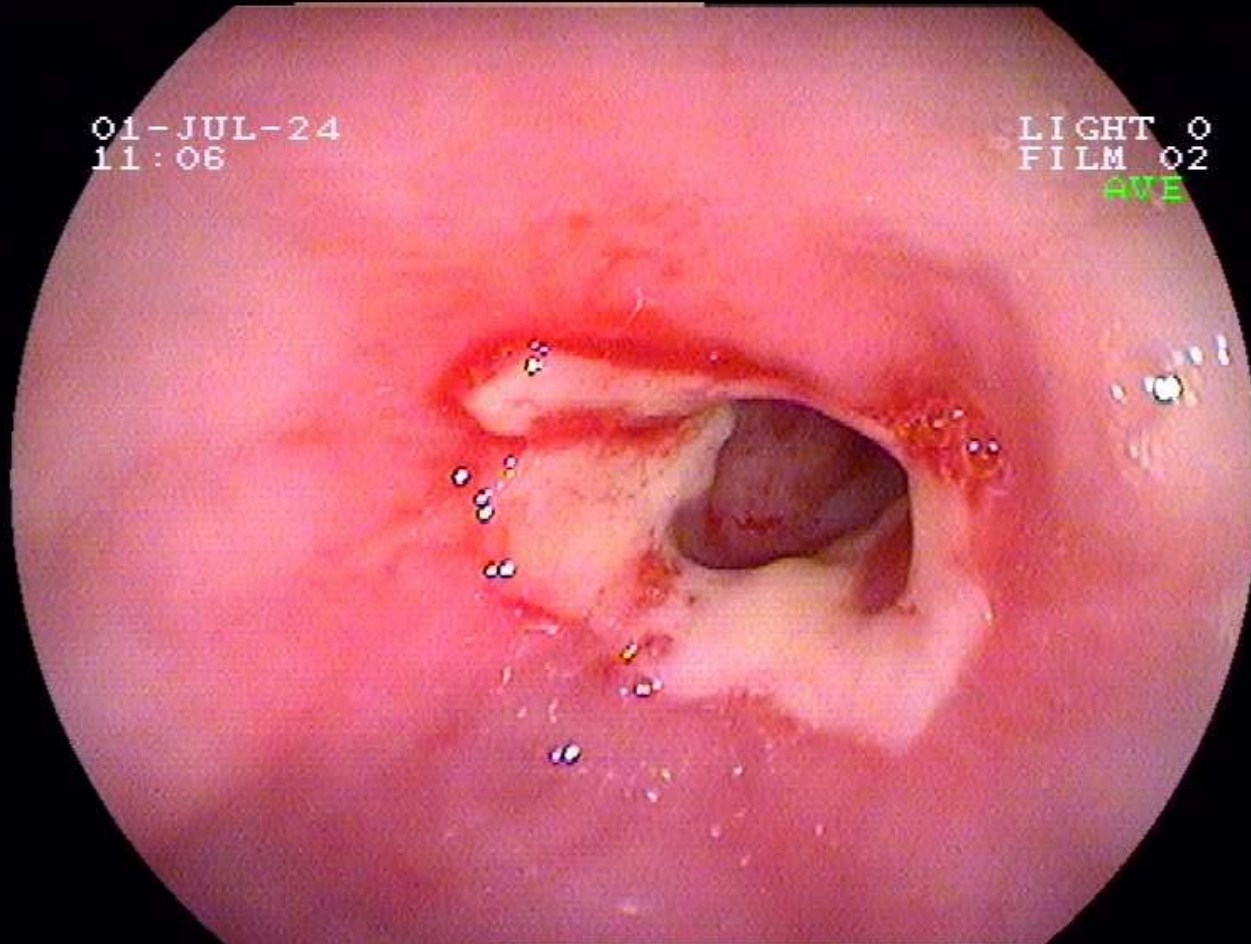
Savary-Miller - Klassifikation



Grad IV: Komplikationen: **Ulcera**, Striktur, (Barrett)

Reflux-Oesophagitis

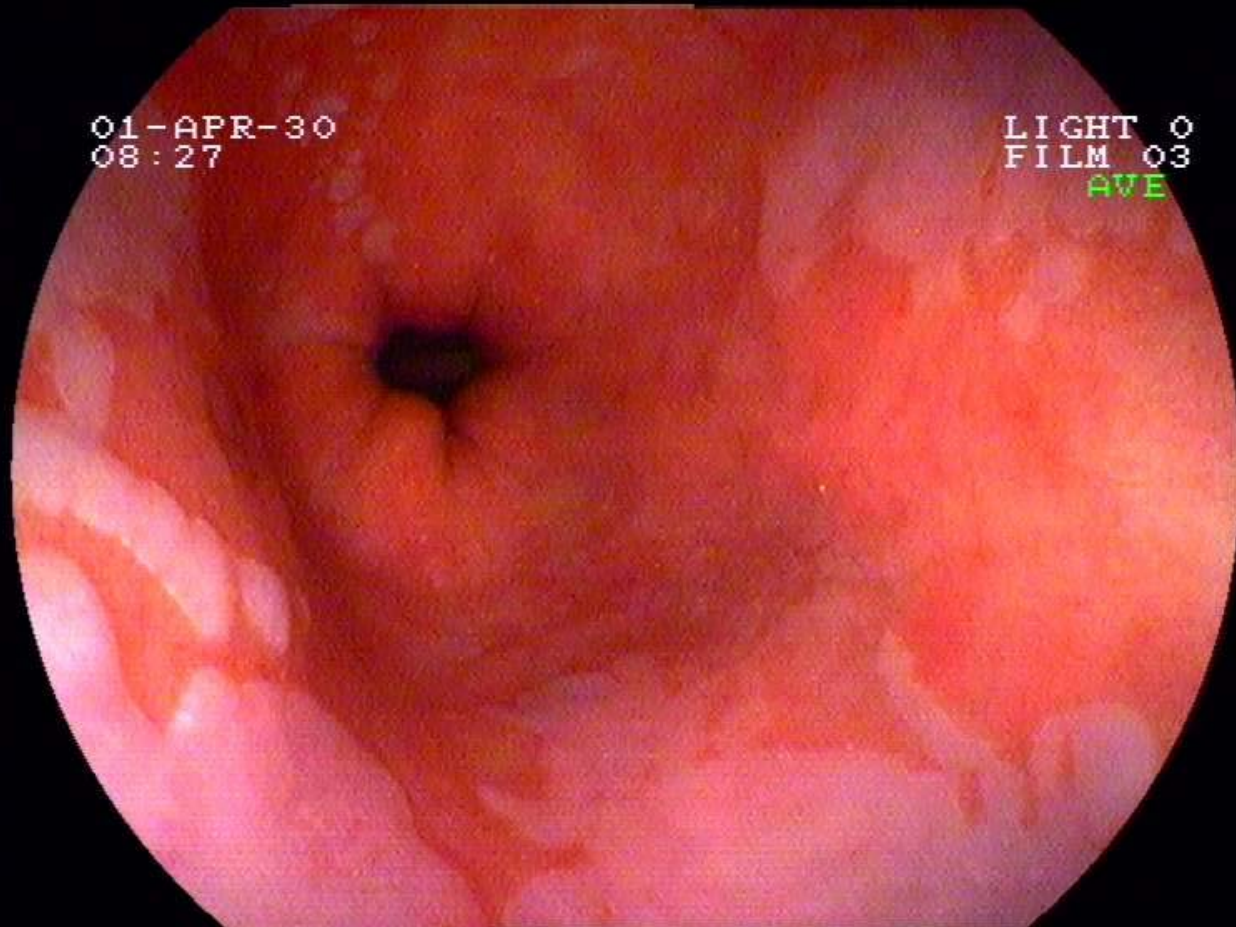
Savary-Miller - Klassifikation



Grad IV: Komplikationen: Ulcera, **Striktur**, (Barrett)

Reflux-Oesophagitis

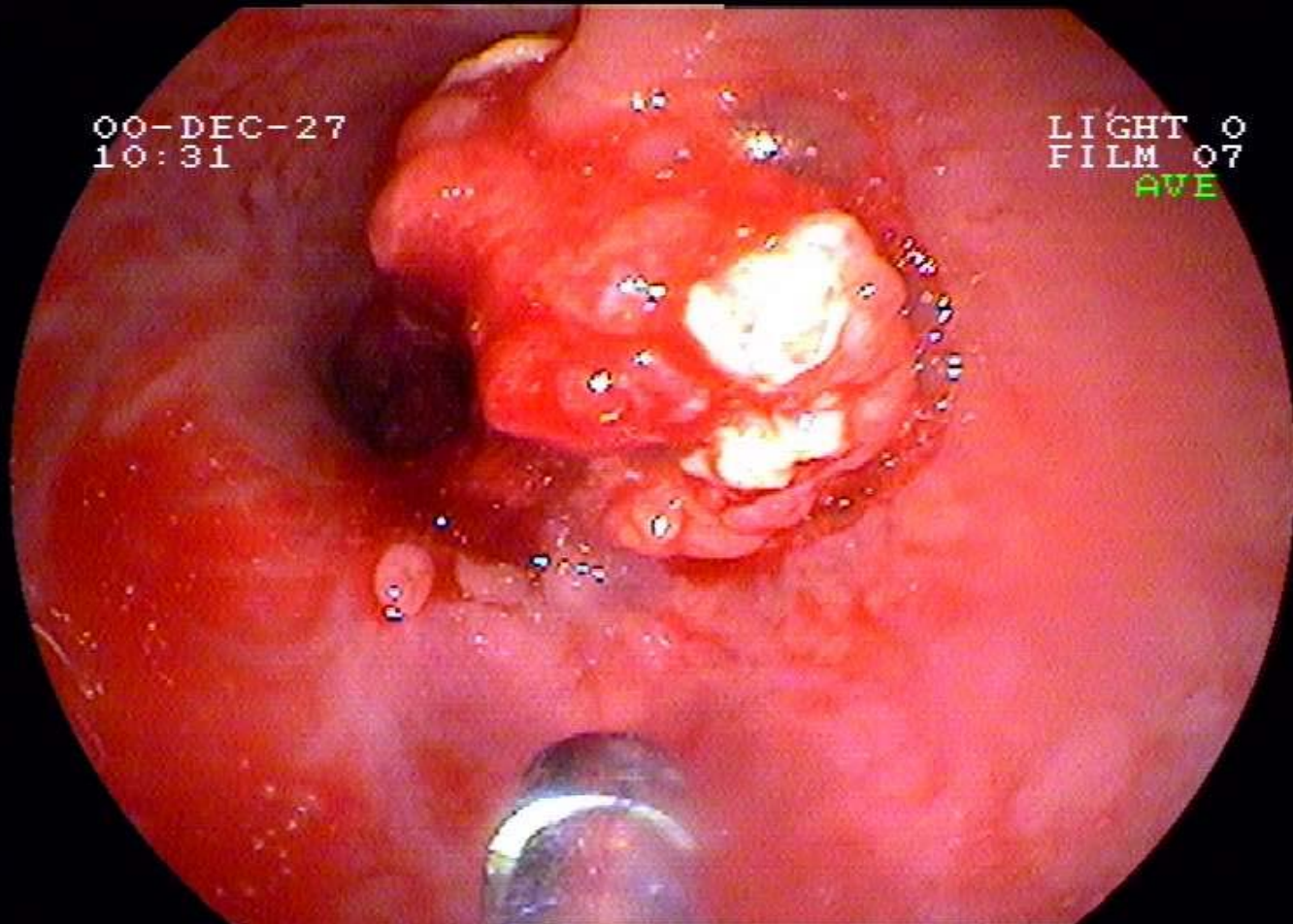
Savary-Miller - Klassifikation



Grad IV: Komplikationen: Ulcera, Striktur, (Barrett)

Reflux-Oesophagitis

Spät-Komplikationen



Oesophagus-(Adeno)-Karzinom